

## Recurrent Tibial Tunnel Cyst Formation Following Anterior Cruciate Ligament Reconstruction and Interference Screw Removal

Jennifer C. Teeters, Michelle A. Cleary, Lindsey E. Eberman, & Jennifer L. Doherty

**Abstract:** A unique case of a collegiate athlete who suffered an anterior cruciate ligament injury leading to the formation of a synovial cyst is described. The cyst, localized over the tibial tunnel, resulted from irritation caused by the removal of interference screws.

The anterior cruciate ligament (ACL) is one of the four major ligaments of the knee and is regarded as the most critical stabilizer. The ACL stretches from the anterior aspect of the intercondyloid fossa of the tibia just medial and posterior to the anterior tibial spine in a superior, posterior direction to the posterior medial surface of the lateral condyle of the femur. The primary responsibility of the ACL is to prevent anteroposterior displacement of the tibia and restrict rotation of the femur upon the tibia. Although the four ligaments of the knee work as a complex unit to stabilize against various forces, an ACL sprain is considered the most serious ligament injury in the knee (Jenkins, 2002). The ACL is the most frequently ruptured ligament of the knee (Beckett, Massie, Bowers, & Stoll, 1992). The mechanism of ACL injury is often described as non-contact with 71% to 78% of ACL-injured patients describing non-contact mechanisms of injury (Woodford-Rogers, Cyphert, & Denegar, 1994).

Given the severity of ACL sprains, reconstructive surgery is often warranted and is performed using autograft (tissue from one's own body) or allograft (tissue from a cadaver). Use of a tissue graft from the semitendinosus muscle, tensor fascia latae, or, most commonly, the patellar tendon satisfactorily results in increasing stability and function (Buss, Warren, Wickiewicz, Galinat, & Panariello, 1993; Kartus, Magnusson, Stener, Brandsson, Eriksson, & Karlsson, 1999; Tierney, Wright, Smith, & Fischer, 1995). Successful outcome is a function of the graft selection, placement, fixation, and healing as well as repair of secondary restraints. The reconstruction must be able to withstand aggressive, immediate post-operative rehabilitation. As a result, numerous fixation techniques have been developed, yet controversy remains as to which one is ideal (Randall, Wolf, Heilmann, & Lotz, 1999). Most surgeons today use hardware for fixation of the graft outside [EndoButton® (Acufex Microsurgical Inc, Mansfield, MA), suture, post-screw, staple] or inside (nonresorbable and resorbable interference screws, cross pin) the drill holes (Paessler & Mastrokalos, 2003). Ultimately the goal of an ACL reconstruction is to improve the functional capacity of the knee and to prevent further damage to secondary dynamic restraints such as menisci, muscles, and tendons. ACL reconstructions have traditionally required short-stay hospitalizations for adequate pain management and nursing care. However, advances in technology and improvements in technique have reduced operative time for ACL reconstructions and decreased the risk of postoperative complications (Tierney et al., 1995).

A commonplace outpatient surgery, ACL reconstruction rarely results in complications (Tierney, et al., 1995). While complications are few, when they occur they include stiffness, quadriceps weakness, bleeding, swelling, and infection (Kartus et al., 1999). Synovial cyst formation over the tibial tunnel is a rare complication after ACL reconstruction (Deie, Sumen, Ochi, Murakami, Fujimoto, & Ikuta, 2000; Feldmann, & Fanelli, 2001; Martinek & Friederich, 1999; Simonian, Wickiewicz, O'Brien, Dines, Schatz, & Warren, 1998; Victoroff, Paulos, Beck,

& Goodfellow, 1995). The objective of this investigation was to raise awareness of allied medical professionals of synovial cysts, a rare adverse outcome of ACL reconstruction.

### **Background and Significance**

*Case presentation.* A National Collegiate Athletics Association Division I baseball player (labeled as LP throughout this report to protect anonymity) presented a case of an unusual fluid filled cyst localized over the tibial tunnel. LP, a 21 year old male senior second baseman (height = 185 cm, weight = 89 kg), had his ACL reconstructed using a semitendinosus graft about nine years prior to his presentation to the primary investigator. Approximately five years after the ACL reconstruction, LP began to experience mild discomfort over the tibial tunnel and the discomfort was thought to be related to the interference screws used in the initial ACL surgery. In an attempt to relieve pain, surgical removal of the screws was suggested. The procedure was completed, rehabilitation was initiated, and, within two months, LP was cleared to return to activity without limitations. Ten months following the screw removal, the patient again reported pain and point tenderness localized over the tibial tunnel. The pain was attributed to a contusion sustained during practice and was treated conventionally. The certified athletic trainer documented all signs and symptoms and monitored the patient's progress daily. In addition to the lack of improvement after two weeks of treatment, LP exhibited signs of a cyst formation (2 x 2 cm mass). Further investigation was necessary; LP was again referred to the team physician. Evaluation by the team physician revealed development of insidious onset swelling at the harvest and tibial tunnel site incision. The area was swollen, red, and warm but within a week, the swelling had consolidated into a thick, fibrous mass (Surgical Notes, 2002a).

*Radiological imaging.* The physician's primary concern was to monitor any structural changes of the tibial tunnel and cyst; therefore a magnetic resonance image (MRI) was ordered. The MRI, defined as a type of radiography using electromagnetic energy, is a valuable diagnostic technique when providing soft-tissue images of central-nervous and musculoskeletal systems (Thomas, 1997). In regular practice, an MRI is a procedure in which the body is exposed to a high-energy magnetic field, which causes hydrogen atoms in water molecules to align themselves. When the current is shut off, the atoms continue to spin, emitting an energy that is detected by the computer. The hydrogen atoms of water molecules in different tissues spin at different rates, thus producing different images. White areas of the MRI image indicate a high signal or high water content, and black areas indicate a low signal or low water content (Arnheim & Prentice, 2000). Sagittal, axial, and coronal imaging of the tibial tunnel illustrated fluid extending into the soft tissues through the tunnel corresponding to the area of palpable abnormality (4 x 2 x 4 cm). On the sagittal images (Figure 1), the ACL graft appeared to be intact; post surgical changes in the distal femur and proximal tibia were obvious. The radiologists' impression of the MRI revealed that the soft tissue mass was a collection of fluid in the tibial tunnel extending from approximately 5 mm distal to the proximal tibia into the subcutaneous region. High signal adjacent to this area in the soft tissues may represent edema or minimal fluid extravasation (Radiology Report, 2002). The evaluation process continued over the next two weeks during which time the cyst maintained its size, and the patient's pain and point tenderness had resolved. The team physician allowed LP to participate as tolerated.

*Cyst excision procedure.* LP participated throughout the remainder of the baseball season without pain. At the completion of the school year, LP underwent excision of the cyst. Review of surgical notes (2002b) prior to the surgical excision of the cyst indicated no family history of disease and no known drug or food allergies. Physical exam revealed that the patient is well developed, well nourished, alert and oriented, with normal mood and affect. Review of the

cardiovascular system concluded no significant edema or varicosities noted in extremities and circulation appeared normal. Examination of the skin around the knee was within normal texture and appearance. Respiration effort was unlabored and normal and sensory function was within normal limits. Results of the musculoskeletal exam revealed the right knee had excellent motion and stability with no mechanical symptoms. An obvious cyst formed over the proximal medial tibia, site of the tibia drill hole. The remainder of the musculoskeletal exam was within normal limits. Results of the surgery were the removal of 4 cc of semisolid fluid from the cyst and an injection of .5 cc of Celestone® (Schering-Plough, Kenilworth, NJ) into the tibial tunnel (Surgical Report, 2002b). Celestone® (betamethasone sodium phosphate) is a synthetic corticosteroid that has similar pharmaceutical actions of cortisone. Important pharmaceutical actions of cortisone include regulatory action as an anti-inflammatory agent (Thomas, 1997). The injection of Celestone® was administered to control the pain localized around the area of discomfort.

*Cyst reformation.* Recovery over the summer from the cyst excision appeared successful, but upon return for the fall semester, the annual pre-participation exam revealed the cyst had refilled to approximately 5 x 5 cm, larger than it was before excision. A re-evaluation rendered no signs of pain or deficiencies in range of motion or strength. The athlete was cleared by the team physician to participate without limitation. A few days into the baseball season, LP was sliding into a base and hit his knee on the ground. The mechanism decompressed the cyst by 0.5 cm but did not cause any pain or trauma to the area. Within one week following the base slide, the cyst had fully decompressed. The sac containing the gelatinous fluid is believed to have ruptured, causing the fluid to leak into the surrounding structures of the knee. Although the rupture decompressed the synovial cyst, one week later the cyst reformed to its larger size as shown in Figure 2a and Figure 2b (Progress Notes, 2002).

### **Methods**

The participant was identified as a patient of the principal investigator while working as an athletic training clinical education student. A signed medical information release waiver was obtained from the participant in accordance with Florida International University Institutional Review Board policies. Data were collected by searching the internet databases MEDLINE, PubMed, and First Search with the following keywords: ACL reconstruction, cyst, ganglion, hamstring, ACL complications, and ACL grafts. The patient's medical files and notes as well as diagnostic testing reports were gathered from the Head Athletic Trainer and Head Team Physician. After gathering all the related data, the publications were analyzed and synthesized to present this unusual case.

### **Results**

A cyst is defined as a closed sac or pouch, with a definite wall, that contains fluid, semifluid, or solid material. It is usually an abnormal structure resulting from developmental anomalies, obstruction of ducts, or parasitic infection (Thomas, 1997). The etiology of these cysts is variable and has been attributed to a number of causes including the use of bioabsorbable screws, Gore-Tex® grafts (W. L. Gore and Associates, Flagstaff, AZ), extra-articular fluid extravasation secondary to direct tibial tunnel communication, patellar tendon or Achilles tendon allografts with or without ethylene oxide sterilization, and use of nonabsorbable sutures (Brettler & Soudry, 1995; Deie et al., 2000; Feldmann et al., 2001; Martinek et al., 1999; Roberts, Drez, McCarthy, & Paine, 1991; Victoroff et al., 1995). Investigations have evaluated the occurrence of complications after arthroscopic ACL reconstruction. A study conducted in Japan followed 89 patients using MRI to detect pretibial cysts as complications after ACL reconstruction using

semitendinosus-gracilis grafts. The researchers found cysts in 2 patients, a rate of 2.2%. The authors concluded that cyst formation occurred as a result of tendon necrosis during the process of incorporation into the osseous tunnel at 6 to 12 months post-surgery (Deie et al., 2000).

At present, nine years after the initial ACL reconstruction, the patient's cyst has maintained its size of 5 x 5 cm and remains dormant and pain free; therefore he has been cleared to play without limitation. In the future, LP understands that this area could be debrided surgically if the cyst recurs. Another possible treatment would be placement of a supplemental bone graft in the area to try to create some type of seal from the tibial drill hole. At this time, LP is doing well clinically, understands his options, and will return to the athletic training room for treatment on an as needed basis.

### **Discussion**

Pretibial cyst formation is a rare complication after arthroscopic ACL reconstruction. For the Certified Athletic Trainer, the outward signs of synovial cysts mimic those of a contusion, just as in this case in which the sports medicine staff observed a direct contact mechanism, raised skin, point tenderness, and pain localized over the tibial tunnel. Studies confirm that a small percentage of patients who undergo ACL reconstructions develop complications. Complications developed in these studies were believed to be associated with an incomplete graft, excessive irritation caused by interference screws, the materials used in the making interference screws, or nonabsorbable sutures left in the graft (Brettler & Soudry, 1995; Deie et al., 2000; Simonian et al., 1998; Victoroff et al., 1995). Most cases involving synovial cysts exhibit formation within two years of an ACL reconstruction (Sekiya, Elkousy, & Fu, 2004). What is unusual about this case is that it first occurred more than 5 years after the ACL reconstruction, and few cases have reported cyst formation resulting from irritation caused by the removal of interference screws.

### **Clinical Implications**

Significance of this case study lies in early recognition of complications that may occur following an ACL reconstruction. Although synovial cysts are a rare complication, it is important for Certified Athletic Trainers to identify signs and symptoms associated with a synovial cyst and refer appropriately. A prompt referral ensures early treatment and may ultimately prevent the cyst from impeding athletic performance.

### **References**

- Arnheim, D. D., & Prentice, W. E. (2000). *Principles of athletic training* (10<sup>th</sup> ed.). Boston, MA: McGraw-Hill.
- Beckett, M. E., Massie, D. L., Bowers, K. D., & Stoll, D. A. (1992). Incidence of hyperpronation in the ACL injured knee: A clinical perspective. *The Journal of Athletic Training*, 27, 58-62.
- Brettler, D., & Soudry, M. (1995). Tibial bone plug resorption with extra-articular cyst: A rare complication of anterior cruciate ligament reconstruction. *Arthroscopy: The Journal of Arthroscopic and Related Surgery*, 11(4), 478-481.
- Buss, D. D., Warren, R. F., Wickiewicz, T. L., Galinat, B. J., & Panariello, R. (1993). Arthroscopically assisted reconstruction of the anterior cruciate ligament with the use of autogenous patellar-ligament grafts. *The Journal of Bone and Joint Surgery America*, 75(9), 1346-1355.
- Deie, M., Sumen, Y., Ochi, M., Murakami, Y., Fujimoto, E., & Ikuta, Y. (2000). Pretibial cyst formation after anterior cruciate ligament reconstruction using auto hamstring grafts: Two case reports in a prospective study of 89 cases. *Magnetic Resonance Imaging*, 18(8), 973-977.

- Feldmann, D. D., & Fanelli, G. C. (2001). Development of a synovial cyst following anterior cruciate ligament reconstruction. *Arthroscopy: The Journal of Arthroscopic and Related Surgery*, 17(2), 200-202.
- Ilahi, O. A., Younas, S. A., & Sahani, I. K. (2003). Pretibial cyst formation after arthroscopic anterior cruciate ligament reconstruction. *Arthroscopy: The Journal of Arthroscopic and Related Surgery*, 19(2), E5-E8.
- Jenkins, D. B. (1998). *Hollinshead's Functional Anatomy of the Limbs and Back* (7<sup>th</sup> ed.). Philadelphia, PA: W. B. Saunders Company.
- Kartus, J., Magnusson, L., Stener, S., Bandsson, S., Eriksson, B., & Karisson, J. (1999). Complications following arthroscopic anterior cruciate ligament reconstruction: A 2-5 year follow-up of 604 patients with special emphasis on anterior knee pain. *Knee Surgery, Sports Traumatology, Arthroscopy*, 7, 2-8.
- Martinek, V., & Friederich, N. F. (1999). Tibial and pretibial cyst formation after anterior cruciate ligament reconstruction with bioabsorbable interference screw fixation. *Arthroscopy: The Journal of Arthroscopic and Related Surgery*, 15, 317-320.
- Paessler, H. H., & Mastrokalos, D. S. (2003). Anterior cruciate ligament reconstruction using semitendinosus and gracilis tendons, bone patellar tendon, or quadriceps tendon-graft with press-fit fixation without hardware: A new and innovative procedure. *Orthopedic Clinics of North America*, 34, 49-64.
- Progress Notes. (2002). Johns Hopkins Division of Sports Medicine, 3400 N. Charles Street Baltimore, Maryland 21218.
- Radiology Report. (2002). American Radiology - Timonium Crossing, 2080 York Road Suite 160 Timonium, MD 21093.
- Randall, R. L., Wolf, E. M., Heilmann, M. R., & Lotz, J. (1999). Comparison of bone-patellar tendon-bone interference screw fixation and hamstring transfemoral screw fixation in the anterior cruciate ligament reconstruction. *Orthopedics*, 22(6), 587-591.
- Roberts, T. S., Drez, D., McCarthy, W., & Paine, R. (1991). Anterior cruciate ligament reconstruction using freeze-dried, ethylene oxide-sterilized, bone-patellar tendon-bone allografts: Two year results in thirty-six patients. *American Journal of Sports Medicine*, 19, 35-41.
- Sekiya, J. K., Elkousy, H. A., & Fu, F. H. (2004). Recurrent pretibial ganglion cyst formation over five years after anterior cruciate ligament reconstruction. *Arthroscopy: The Journal of Arthroscopic and Related Surgery*, 20(3), 317-321.
- Simonian, P. T., Wickiewicz, T. L., O'Brien, S. J., Dines, J. S., Schatz, J. A., & Warren R. F. (1998). Pretibial cyst formation after anterior cruciate ligament surgery with soft tissue autografts. *Arthroscopy: The Journal of Arthroscopic and Related Surgery*, 14, 215-220.
- Surgical Notes. (2002a). Johns Hopkins Medical Institution - Greenspring Clinic, 10755 Falls Road Lutherville, MD 21093.
- Surgical Notes. (2002 b). Orthopedic and Arthritis Center - McBride Clinic, 1110 N. Lee Oklahoma City, Oklahoma 73103.
- Thomas, C. L. (1997). *Taber's Cyclopedic Medical Dictionary* (18<sup>th</sup> ed.). Philadelphia, PA: F.A. Davis Company.
- Tierney, G. S., Wright, R. W., Smith J. P., & Fischer, D. A. (1995). Anterior cruciate ligament reconstruction as an outpatient procedure. *American Journal of Sports Medicine*, 23(6), 755-766.

Victoroff, B. N., Paulos, L., Beck, C., & Goodfellow, D. B. (1995). Subcutaneous pretibial cyst formation associated with anterior cruciate ligament allografts: A report of four cases and literature review. *Arthroscopy: The Journal of Arthroscopic and Related Surgery*, 11(4), 486-494.

Woodford-Rogers, B., Cyphert, L., & Denegar, C. R. (1994). Risk factors for anterior cruciate ligament injury in high school and college athletes. *The Journal of Athletic Training*, 29(4), 343-346.

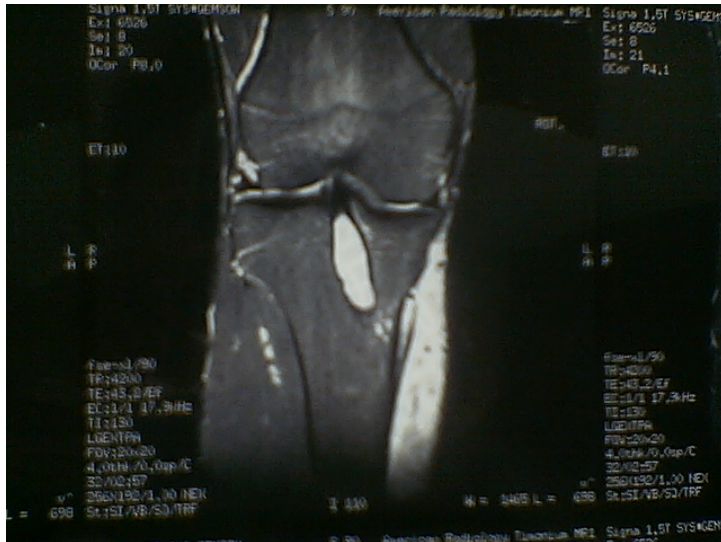


Figure 1. Magnetic resonance image (sagittal view) revealing fluid inside the tibial tunnel.

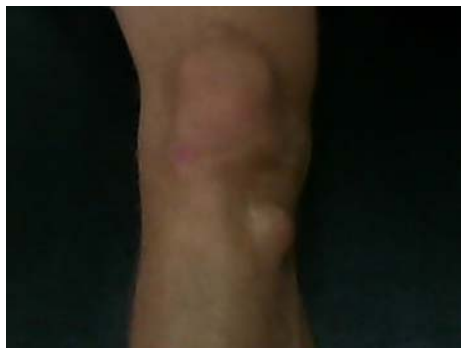

Figure 2a

Figure 2a. Anterior view of the cyst as it appears today.

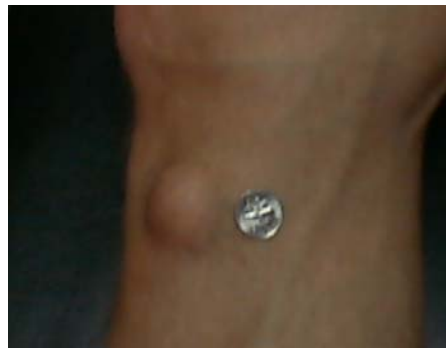

Figure 2b

Figure 2b. Reformed synovial cyst over tibial tunnel with dime for reference size.