

1-15-2015

# Application of Robotic Surgery in the treatment of endometriosis: View point of an Indian OBGYN fellow in USA

Krishna Kavita Ramavath  
*South Florida Baptist Hospital*

Manuel A. Penalver  
*Herbert Wertheim College of Medicine, Florida International University, mapenalv@fiu.edu*

Luis E. Mendez  
*South Florida Gynecological Oncologist, Doctors Hospital*

Olyai Roza  
*Olyai Hospital*

Follow this and additional works at: [http://digitalcommons.fiu.edu/com\\_facpub](http://digitalcommons.fiu.edu/com_facpub)

 Part of the [Medicine and Health Sciences Commons](#)

---

## Recommended Citation

Ramavath, Krishna Kavita; Penalver, Manuel A.; Mendez, Luis E.; and Roza, Olyai, "Application of Robotic Surgery in the treatment of endometriosis: View point of an Indian OBGYN fellow in USA" (2015). *HWCOC Faculty Publications*. 101.  
[http://digitalcommons.fiu.edu/com\\_facpub/101](http://digitalcommons.fiu.edu/com_facpub/101)

This work is brought to you for free and open access by the Herbert Wertheim College of Medicine at FIU Digital Commons. It has been accepted for inclusion in HWCOC Faculty Publications by an authorized administrator of FIU Digital Commons. For more information, please contact [dcc@fiu.edu](mailto:dcc@fiu.edu).

DOI: 10.5455/2320-1770.ijrcog20150236

Research Article

## Application of Robotic Surgery in the treatment of endometriosis: View point of an Indian OBGYN fellow in USA

Krishna Kavita Ramavath<sup>1\*</sup>, Manuel A. Penalver<sup>2</sup>, Luis E. Mendez<sup>3</sup>, Olyai Roza<sup>4</sup>

<sup>1</sup>Physician Observer Fellow, South Florida Baptist Hospital, Affiliated to Florida International University, Florida, USA

<sup>2</sup>Chair of Obstetrics & Gynecology, Florida International University, Florida, USA

<sup>3</sup>South Florida Gynecological Oncologist, Doctors Hospital, Coral Gables, Florida, USA

<sup>4</sup>Olyai Hospital, Gwalior, Madhya Pradesh, India

**Received:** 22 December 2014, **Revised:** 3 January 2015

**Accepted:** 15 January 2015

**\*Correspondence:**

Dr. Krishna Kavita Ramavath,

E-mail: drkavita18@yahoo.com

**Copyright:** © the author(s), publisher and licensee Medip Academy. This is an open-access article distributed under the terms of the Creative Commons Attribution Non-Commercial License, which permits unrestricted non-commercial use, distribution, and reproduction in any medium, provided the original work is properly cited.

### ABSTRACT

**Background:** This article is an observational experience of robotic surgery in USA by an Indian Obgyn fellow. Primary objective is to analyze retrospectively peri operative outcomes in stage 2 and 3 Endometriosis treated with robot assisted laparoscopy. Secondary objective is to report an Indian Obgyn, Physician observer fellows experience in USA with Robotic surgery.

**Methods:** 29 women underwent robotic surgery at in the department of gynecology at Doctor's hospital, Baptist health, Miami. Pre-op time, console time, total operative time, blood loss, peri-operative complications noted.

**Results:** Mean age is  $42 \pm 8$  years with BMI of  $26.2 \pm 8$  kg/m<sup>2</sup>. Eighteen patients (62%) were age 40 and above. Twenty patients (69%) presented with chronic pelvic pain. Dyspareunia in 16 (55.2%), bloating in five (17.2%) and pelvic mass in thirteen (44.8%) Unilateral pelvic mass in nine patients (31 %) and bilateral in four patients (13.8%). CA 125 levels are elevated in nine patients (31%) and significantly higher with endometriomas ( $76.1 \pm 49.2$  U/ml). 38% underwent robot assisted laparoscopic hysterectomy and BSO. 14.8% underwent robot assisted laparoscopic hysterectomy with Robot (LSO/RSO). Mean operative time 64.7 min. Mean blood loss 40 ml.

**Conclusions:** Robotic surgery is safe, with minimal blood loss and shorter hospital stay. Alike in the surgical techniques, though diverse in the work infrastructure and technology, East and West have common scenarios which can be tackled with exchange of training opportunities. This interchange of knowledge and skills will benefit patients with increased surgeon's efficiency.

**Keywords:** Endometriosis, Robotic surgery, Surgical outcomes, da vinci, Minimal invasive surgery

### INTRODUCTION

Several surgical subspecialties, such as cardiac, urological, gynecological, and general surgery have embraced the use of robotic systems. This latest and most sophisticated innovation in technology has revolutionized the practice of surgical scenario in gynecology in recent years.<sup>1</sup> Evolution of the technology and training

opportunities in USA have given a definite advantage to the gynecologists here than the rest of the world.

Fascinated by the fabulous robotic surgeries I came to USA, from India, to get trained in the advanced minimally invasive surgical techniques. I was one of the few International participants authorized to shadow the doctors with in BHSF facilities including OR cases. This program is not a sponsored one but the candidates are

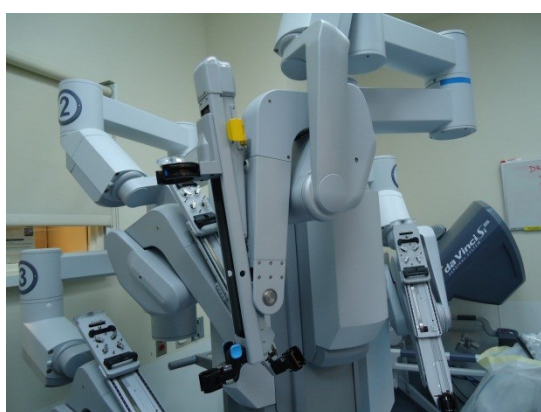
merit listed and those with a passion in the field are invited. I had the distinct pleasure of being closely associated with highly skilled robotic surgeons. Though I did not personally assist any robotic procedures, I had the opportunity to watch many interesting robotic cases and even attended two different hospitals due to huge volume of robotics performed and utilized time in between for research activities.

The application of robot assisted laparoscopy in the treatment of Endometriosis was found to have excellent outcomes. It has been successfully used in the treatment of endometriosis when compared to classical laparoscopy (Nezhat et al., 2009).<sup>2</sup> Endometriosis has been linked with chronic pelvic pain, decreased quality of life, and Infertility.<sup>3</sup> This increasingly important condition continues to attract gynecologists debate worldwide.

## METHODS

Peri-operative outcomes were analyzed retrospectively for the 29 patients with Endometriosis, from Jan 2013 to May 2013 who presented to the department of gynecological oncology at Doctor's hospital, Baptist health South Florida, Miami with a combination of symptoms of pelvic pain, menorrhagia, bloating, dyspareunia and pelvic mass.

All the patients underwent robotic assisted laparoscopic surgery by two board certified gynecologic oncologists and were diagnosed with stage 2 and 3 endometriosis (Revised ASRM staging). The primary author is closely associated with both of the surgeons and followed all patients peri-operatively. Complete notes of the primary author are meticulously reviewed by all authors of the study for accuracy. The da Vinci robotic surgical system (Intuitive Surgical, Sunnyvale, CA) was used on all patients (Figure 1) ( da Vinci robot).



**Figure 1: da Vinci robot used in the study.**

With more than 600 robotic cases done per year by both the surgeons, doctors' hospital is one of the busiest robotic gynecological surgical programs in Miami. There is a strong referral relationship with the community gynecologists and family physicians. The hospital is

affiliated to FIU (Florida International University of Medicine)

Records were reviewed retrospectively for demographics, BMI, presenting symptoms, CA 125 levels, USG report, and prior medical and surgical histories. Operative outcomes have been analyzed for all the cases which included total operative time, docking time including robot assembly and disassembly time, estimated blood loss, duration of hospital stay, intra operative complications, conversion to laparotomy, post-operative complications and blood transfusions.

During the study period, 170 robotic surgeries are performed and among them 20 patients were diagnosed as stage 2 and 9 patients were diagnosed with stage 3 endometriosis.

Table 1 summarizes the clinical characteristics of the patients.

**Table 1: Clinical characteristics of the patients.**

Characteristic	Details
<b>Age, y ± SD</b>	42 ± 8 years
<b>BMI, kg/m<sup>2</sup></b>	26.2 ± 8 kg/m <sup>2</sup>
<b>Symptoms of presentation</b>	<b>n (%)</b>
Chronic pelvic pain	20 (68%)
Dyspareunia	16 (55.2%)
Dysmenorrhea & menorrhagia	7 (24.1%)
Pelvic mass	13 (44.8%)
Unilateral	9 (31%)
Bilateral	4 (13.8%)
Bloating	5 (17.2%)
Previous ovarian surgery	7 (24.1%)
Infertility	6 (20.7%)
Ca 125 levels, U/ml ± SD	76.7 ± 52.2
High Ca 125 levels	9 (31%)

Both of the operating surgeons performed the staging of Endometriosis using revised ASRM guidelines. All the procedures were performed in the OR dedicated to robotic surgeries with a skilled team.

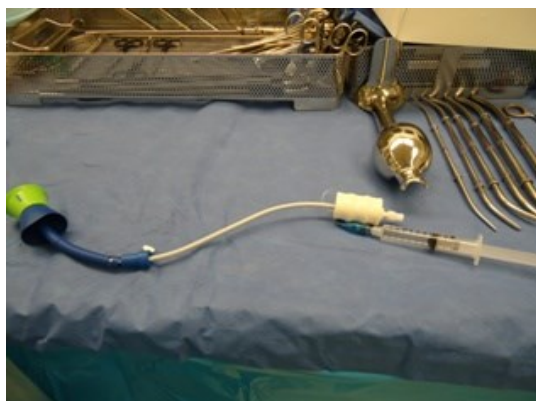An efficient team work makes all the difference to have a smooth ride during the management of a difficult case.

### *Pre-operative setup*

Includes patient timeout protocol, induction of endotracheal anesthesia, patient positioning and testing of toleration of steep Trendelenburg. The patient prepped and draped with gel pads underneath for stability. Egg-crater pads were used underneath the arms and legs to prevent nerve damage.

A Foley catheter is placed followed by insertion of V-care or Harris-Kronner Uterine Manipulator Injector

(HUMI) which aid in the visualization of the pelvis (Figure 2) (V-care uterine manipulator/elevator).



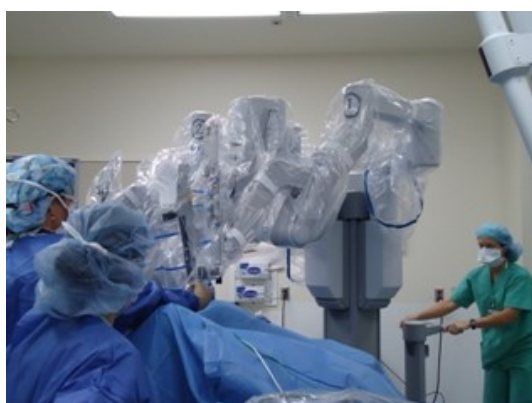**Figure 2: V-care manipulator.**

Pre-operative single dose antibiotic is given routinely to every patient. With the placement of trocars and establishment of pneumo peritoneum, the patient is ready for the docking of the da Vinci robotic system

#### **Port sites**

Four trocar sites were placed: an initial 12-mm trocar was placed supra umbilical, two lower lateral, 8-mm in the right and left quadrants, and a 12-mm trocar in the right lower quadrant for the assistant to change the instruments needed during robot usage. Initially laparoscopy was performed on every case and then switched to robotic-assisted surgery. Insertion of robotic 3D camera after removal of the laparoscopic camera is followed by docking of the two robotic arms to the two 8-mm trocars.

Whether it is the medial docking of the patient-side surgical cart, which was placed in the middle, or lateral docking next to the patient's legs, depends on the choice of the surgeon. In this study, each surgeon has a specific preference with one using medial and the other using lateral docking (Figure 3) (Lateral docking of the draped Robot).



**Figure 3: Lateral docking of the draped Robot.**

#### **Surgical technique**

Robot assisted laparoscopic hysterectomy is performed after general anesthesia. Steep Trendelenburg position is used. After the initial laparoscopy with creation of pneumo peritoneum by Veress needle, robotic video laparoscope is introduced through initial 12mm supra umbilical port. Abdomen is explored to see the extent of endometriosis. Then the two robotic 8 mm trocars and 12 mm assistant trocar in the right lower quadrant is introduced.


The equipment used for the laparoscopy included a Ligasure, monopolar and bipolar system. For the robotic portion, a needle holder, bipolar, and monopolar scissors are used.

Surgeon at the console starts to isolate and transect the infundibulopelvic ligaments and round ligaments. The ureters are carefully identified with retroperitoneal dissection. Ligasure is used to coagulate and transect uterine vessels and ligaments.

Bladder is separated from lower uterine segment with blunt dissection. With continuous pressure on the uterine manipulator by the assistant a demarcation of the cervico-vaginal junction is seen. Monopolar scissors is used to perform circumferential colpotomy. The specimen of the uterus is then removed enbloc with both ovaries trans vaginally.

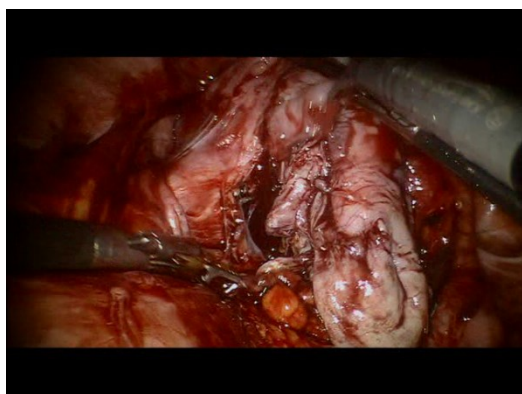
All the endometrial lesions seen are removed. Cuff closure is done with V-loc non-absorbable knotless barbed suture which reduces operative times. We routinely used EVICEL® Fibrin Sealant (Human) for general hemostasis after the procedure.

Excision of endometriomas is done carefully. In cases with elevated CA125 levels we routinely performed frozen sections, confirmed with histology and documented.

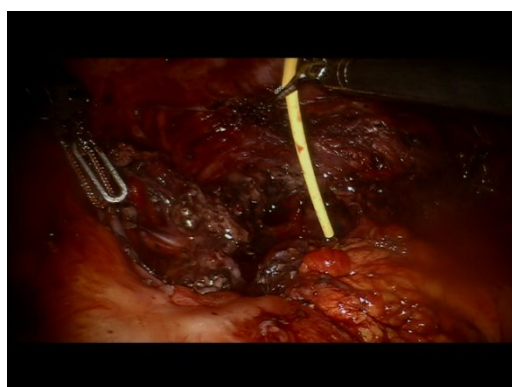


**Figure 4: Frozen Section in the lab adjacent to the OR.**

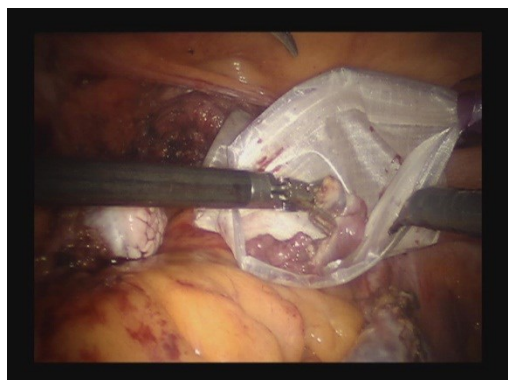




**Figure 5: Endometrioma.**



**Figure 6: Evicel fibrin sealent.**



**Figure 7: Endo bag for specimen retrieval.**

### Statistical analysis

We analyzed retrospectively our collected data. Descriptive analysis of the operative details is done including, pre-op time, console time, total operative time, estimated blood loss, intra and post-operative complications and hospital stay. Analyzed data is represented as percentage and/or mean  $\pm$  Standard Deviation (SD). The time taken between switching from laparoscopy to robot was measured as assembly time. The disassembly time was defined as the time taken to switch from the robot back to laparoscopy to close the trocar sites.

### RESULTS

During the study period, 29 patients underwent robotic assisted laparoscopic procedures for symptomatic endometriosis. Most of the patients were referred by family physicians who recommended definitive therapy for the chronic pelvic pain or recurrent endometriosis. The mean age of the study group is  $42 \pm 8$  years with BMI of  $26.2 \pm 8$  kg/m<sup>2</sup> (Table 1).

Among them, eighteen patients (62%) were age 40 and above. Seven (24.1%) patients had previous surgeries like USO, ovarian cystectomies, endometrioma excisions by laparoscopy. Twenty patients (69%) presented with abdominal or chronic pelvic pain and other pre-operative symptoms were dyspareunia in sixteen (55.2%), infertility in six (20.7%), menorrhagia and dysmenorrhea in seven (24.1%) bloating in five (17.2%) and pelvic mass in thirteen (44.8%) Unilateral pelvic mass is seen in nine patients (31 %) and bilateral in four patients (13.8 %) co- existing fibroids are seen in seven (24.1%) and they were referred due to pelvic mass as a chief complaint. CA 125 levels are elevated in nine patients (31%). The CA125 concentration was significantly higher in females with endometriomas ( $76.1 \pm 49.2$  U/ml). Intra operative findings showed endometriomas in seven patients (24.1%). The presence of superficial and deep endometriotic implants, endometriomas and pelvic adhesions was documented in Table 2.

**Table 2: Endometriosis characteristics intra-operatively.**

Characteristic	n%
<b>Endometrioma</b>	7 (24.1%)
Left ovary	4 (13.8%)
Right ovary	3 (10.3%)
<b>Superficial peritoneal endometriosis</b>	12 (41.4%)
<b>Deep peritoneal endometriosis</b>	3 (10.3%)
<b>Adnexal adhesions</b>	
<8	Nil
8-16	20 (69%)
>16	9 (31%)

Revised ASRM classification is used for adhesions calculations. Stage-I (minimal, 1-5), Stage-II (mild, 6-15), Stage-III (moderate, 16-40), Stage-IV (severe, >40)

Superficial peritoneal endometriosis is seen in 12 patients. Adenaxal adhesions were mild in 20 patients (69%) and moderate in 9 patients (31%).

One patient (3.4%) had severe endometriosis with adhesions to the pelvic sidewall visualized during Robot assisted laparoscopy, and converted to exploratory laparotomy with total abdominal hysterectomy.

Table 3 shows the different types of robotic- assisted surgeries performed during the study by both surgeons.

**Table 3: Distribution of Robotic surgeries for endometriosis.**

Name of surgery	Number of Robotic surgeries n (%)
Robotic TAH w/- BSO	11 (37.9%)
Robotic TAH w/- RSO	2 (6.9%)
Robotic TAH w/- LSO	2 (6.9%)
Robotic myomectomy & RSO	1 (3.4%)
Robotic TAH, RSO, left ovarian cystectomy	1 (3.4%)
Robotic BSO	2 (6.9%)
Robotic LSO	3 (10.3%)
Robotic TAH, left ovarian cystectomy	2 (6.9%)
Robotic right ovarian cystectomy	4 (13.8%)
Robot assisted laparoscopy, E-lap, TAH	1 (3.4%)
<b>Total</b>	<b>29 (100%)</b>

Eleven patients (37.9%) underwent robot assisted laparoscopic hysterectomy and bilateral salpingo-oophorectomy. Eight patients (27.6%) underwent robot assisted laparoscopic hysterectomy with unilateral (LSO/RSO) salpingo-oophorectomy. One patient (3.4%) underwent robotic myomectomy and RSO.

Two patients (6.9%) underwent robotic BSO only and three patients (10.3%) underwent robotic LSO only. Two patients (6.9%) had ovarian cystectomies with excision of endometrial implants and removal of the endometriomas. One patient (3.4%) underwent Robot assisted laparoscopy, and converted to exploratory laparotomy and total abdominal hysterectomy due to dense adhesions. She had prior surgery for ovarian endometriomas.

Operative summary and results for all cases were included in Table 4.

**Table 4: Operative summary and results.**

Case #	Pre-operative time (minutes)	Console time (minutes)	Total operative time (minutes)	Blood loss (ml)	Intra and post-operative complications	Robot assembly time (minutes)	Robot dis-assembly time (minutes)
1	68.4	45.3	113.7	45	none	10	2.1
2	76.9	50.2	127.1	45	none	9	2.5
3	69.3	56.1	125.4	45	none	8.6	3.1
4	64.4	40.3	104.7	30	none	7.8	2.4
5	72.2	35.4	107.6	45	none	6.6	2.6
6	71.1	35.3	106.4	50	none	7.5	2.3
7	68.2	38.2	106.4	50	none	6.8	2.2
8	69.1	41.1	110.2	50	none	7.4	2.5
9	68.4	46.1	114.5	30	none	8.9	2.4
10	65.8	40.2	106	50	none	8.8	2.5
11	65.6	48.2	113.8	50	none	9.2	2.2
12	69.3	46.3	115.6	50	none	7.6	2.4
13	67.2	48.7	115.9	50	none	9.3	2.5
14	68.1	39.3	107.4	40	none	6.9	2.4
15	68.4	45.2	113.6	40	none	7.8	2.6
16	64.1	43.7	107.8	45	none	7.9	2.4
17	66.6	44.3	110.9	45	none	8.8	2.3
18	69.1	35.2	104.3	30	none	8.7	2.3
19	66.8	41.2	108	30	Fever	6.7	2.4
20	69.2	34.3	103.5	30	none	8.9	2.5
21	53.1	28.2	81.3	30	none	9.4	2.6
22	69.1	33.3	102.4	40	UTI	8.8	2.2
23	62.2	34.1	96.3	40	none	9.7	2.3
24	64.4	29.8	94.2	30	none	6.8	2.4
25	53.4	52.1	105.5	50	none	9.7	2.6
26	52.1	36.5	88.6	30	none	6.7	2.8
27	55.2	25.7	80.9	30	none	7.7	2.2
28	45.1	26.1	71.2	40	none	8.5	2.4
29	53.1	28.2	75.2	30	none	8.6	2.4
<b>Average of all cases</b>	64.7	39.6	104.1	40.3		8.2	2.4

The mean pre-operative time was 64.7 min. Mean operating time for only unilateral salpingo-oophorectomy is 50.1 (SD 4.3) min, while only bilateral salpingo-oophorectomy took 54.3 (SD 1.2) min. The mean total operative time is 104.3 minutes which includes the mean console time of 39.6 minutes plus mean pre-op time of 64.7 minutes.

The mean assembly time of robot is 8.2 min and the dissembling time is 2.4 minutes. Mean estimated blood loss is 40 ml; length of hospital stay is 1 day.

One case was converted to laparotomy. There was one post-operative case with a complication of UTI and fever. None of the cases needed blood transfusions. Post-operative pain relief was excellent by 8 weeks in 27 patients (93.1%).

We noticed that robotic route to manage endometriosis is 'visualize and manage' approach by which we see and assess the difficulty of the surgery with regard to (adhesions, pathology) and then perform robotic technique best for the situation. Suturing was easier due to the better 3D view of the surgical field. The entire procedure is carried out with clarity and precision and without surgeon's fatigue.

## DISCUSSION

Endometriosis is a chronic inflammatory condition that involves one or many areas of the pelvis, adnexa and abdomen.<sup>4,5</sup> Complete resection of endometriosis has been traditionally considered a challenging operation, even with operative laparoscopy. Robotic technology provides exceptional visual feedback, enhanced surgical ergonomics, and advanced instrumentation critical for success of a difficult pelvic dissection.<sup>6</sup>

Review of literature on the application of Robotic surgery to the treatment of Endometriosis showed only case reports, series or short studies that documented the experience of da vinci surgical system in stage 2 and 3 endometriosis. Nezhat et al. showed that robot assisted laparoscopy could be successfully applied in stage 4 endometriosis.<sup>5</sup>

Most of the patients in the study group who underwent hysterectomy for endometriosis (41%), had an initial laparoscopy performed and they were diagnosed with endometriosis. While gynecologists were able to clear away much of the endometrial tissue at that time, they were told that the endometriosis would come back and they would need to have a hysterectomy within two or three years. However, many didn't want to have major surgery, and so endured the symptoms for years. Finally, when they could no longer endure, with severe pain affecting the quality of life, they turned to these operators with a high level of expertise. They presented with fusion of tissues causing cysts and scars.

The lesions mostly are located in the pelvis and the ovaries. Endometriomas varied in size from 3cms to 10cms with elevated CA 125 levels. They are subjected to frozen section analysis (Figure 4) (frozen section). There are adhesions between the ovaries and the pelvic peritoneum, uterus and cul-de-sac. Scarring, puckering, and hemosiderin staining of peritoneum is also noted.

The patients with elevated CA125 levels were referred to the oncology division with an anticipation of intra-operative difficulty and suspected ovarian cancer. In the present study, the mean serum CA-125 level increased when cases were associated with ovarian endometriomas (Figure 5) (Endometrioma) consistent with findings from most previous studies (Cheng et al., 2002).<sup>7</sup>

Consistent with previous reports, we found both a lower mean blood loss and minimal hospital stay in patients managed robotically.<sup>8</sup> This could be the result of 3D vision and improved depth perception. Precision in the surgery with the absence of tremor and the ergonomic position, provides comfort for the surgeon.<sup>9</sup> We have not experienced any major intra- and/or post-operative complications in our procedures.

Roberta B. Ness et al. found that the odds of developing ovarian cancer were 50% higher among women diagnosed with endometriosis<sup>10</sup> and another case-control study by Brinton and colleagues also found a 2.5- to 3.5-fold increase in endometrioid and clear cell tumors among women with endometriosis.<sup>11</sup> For the patients with elevated CA 125 levels we discussed pre-operatively about the possibility of robotic staging, peritoneal washings, omentectomy and lymphadenectomy if ovarian malignancy is found during surgery. None of them had endometriosis related ovarian cancer.

The symptomatic women in the study who completed the family and desired no more children underwent total robot assisted laparoscopic hysterectomy with BSO, whereas the Infertile women with recurrent endometriosis following conservative surgery underwent Robot assisted unilateral or bilateral salpingo-oophorectomy.

Recent studies have shown an extra time necessary for preoperative setup in robotic cases as a specific factor leading to longer operative times.<sup>12</sup> Shorter OR times can be achieved by any modification that can decrease pre-op setup time.<sup>13,14</sup> In our study the overall mean total operative time was 104.3 min which longer than traditional laparoscopic cases, but compared to other robotic procedural studies is significantly less. This is due to the advanced laparoscopic skills of the operating surgeons. According to Lenihan et al.<sup>15</sup> the learning curve for robotic-assisted surgeries is 50 cases.

A review of literature shows reduction in operative times after the learning curve but little attention is given to the OR team. Our preoperative times decreased from 76.9 min to 52.1 min with a mean preoperative time of 64.7 min and the operative time at the console was only 39.6

minutes. This may be explained by the fact that all 170 cases were performed by both surgeons with the assistance of high quality team cooperation. Using this enhanced team coordination we had significantly decreased preoperative setup time with a dependable OR environment for patient safety. Our data is consistent with previous studies as this seems to be the most cost-effective utilization of the surgical robot in gynecological procedures (Lasser MS, et al. 2012).<sup>16</sup>

The overall median estimated blood loss was 40 ml. No patient received blood transfusion. There were no intra or post-operative complications. One patient had post-operative fever attributed to UTI and her symptoms resolved quickly with treatment. All of them had good recovery and urine output. Catheter was removed as soon as the patient was ambulant. The mean duration of hospital stay was one day. All of the patients underwent the robotic procedures successfully. They had less postoperative pain hence less need for analgesics.

Endometriosis is often a difficult disease to treat as recurrence rates are high. Studies quote that pain relief is noted postoperatively in 50-95%. In a double blind randomized study by Sutton et al, pain relief was significant at one year.<sup>17</sup> Post-surgical adhesions may sometimes continue to be the cause of pain. Parker et al stressed that surgical techniques have to be optimized at reducing post-operative adhesions.<sup>18</sup>

We routinely used EVICEL® Fibrin Sealant (Human) for general hemostasis as drip application after the procedure Figure 6 (EVICEL® Fibrin Sealant).

When questioned about the pain and progress, one of the patients on her first post-operative visit, whose extensive condition required hysterectomy in her words says "Robotic surgery is so much better, I know from experience that it can be hard to get around for a couple of weeks after traditional surgery, but after the robotic procedure, I was moving in a couple of days. I felt better right away, and was back to feeling like I could do anything in just a couple of weeks. It's definitely the way to go." She is one of the many satisfied patients who felt the similar way.

The success of surgery is highly dependent on the expertise and training of the gynecological surgeon performing the robotic procedure. Robotic application is an acceptable safe alternative to traditional laparoscopy, with minimal blood loss, quick recovery, shorter hospital stay and no complications.

The limitations to our study include the retrospective, observational experience design introducing the potential for bias. However, review of literature on the robotic-assisted approach to the management of stage 2 and 3 endometriosis demonstrates that our experience is consistent with the data that is published.

### **View point**

Whether a robot is truly justified in the gynec workforce is a difficult question to answer because of equally potential benefits and drawbacks. Undoubtedly it is a superior tool in the surgical armamentarium and with it also come the drawbacks of huge finances be it be the initial cost or the maintenance of the equipment. But the debate now seems to be settled for the benefits of robotic surgeries.<sup>19,20</sup> While discussing various options for treatment, in my clinical practice, I would definitely discuss robotic surgery as an option offered and explain about the long-term outcomes.

Upon completion of my tenure, I was able to learn to recognize techniques to prevent and repair intra-operative complications, including genito-urinary and vascular injuries, evaluate relevant indications, techniques, and outcomes of robotic surgical procedures, review surgical anatomy of the female pelvis and surgical dissection techniques for complex hysterectomy, endometriosis, myomectomy, and pelvic support procedures.

In reflecting on my experience, the most important thing I've learned is alike in the surgical techniques, though diverse in the work infrastructure and latest technology, East and West have common patient scenarios which can be tackled with exchange of training opportunities. This interchange of knowledge and skills will benefit both countries with an increase in the patient safety and surgeon's efficiency. So in this new age of technology one has to be an increasingly sophisticated learner and need to be associated with experienced surgeons to become all the way, the seasoned professional.

### **CONCLUSION**

This study is first of its kind to present an observational experience of an Indian Obgyn fellow in USA and the role of robot assisted laparoscopy in the management of stage 2 and 3 endometriosis. The revolutionary surgical robots in gynecology offer the promise of overcoming many shortcomings of laparoscopy and numerous studies have demonstrated to date the usefulness of Robotic surgery in the treatment of pelvic endometriosis, thanks to the technology and trained operating surgeons. This article is a helpful addition in the ongoing literature of robot assisted laparoscopy.

As of June 30, 2014, over 3,102 units were installed worldwide with 2,153 units in the United States and the use of robots continues to increase. University based hospitals and community based institutions in US are increasingly adopting the use of robot with Intuitive surgicals providing the surgeon training in an academic setting. Today, robotic technology enhanced our surgeries with great precision, autonomy, and efficiency. Tomorrow the younger generation with more sophisticated skills in computers will see a different world beyond what can be imagined or achieved today.



Gynecologists who develop confidence and have successful results in the treatment of endometriosis, as they adapt to latest technology with the available data, often prefer that method of surgery in the best interests of the patients. We think it is our prime responsibility as gynecologists is to critically evaluate these new developments to ensure the best clinical outcomes to our patients.

## ACKNOWLEDGEMENTS

My sincere thanks to Salvador Betancourt the physician assistant, Diana Acevedo the Robotic coordinator, Iris Garcia practice administrator and Martine P. Hernandez, the library services coordinator of the dept. of gynecology, doctors hospital, Baptist health South Florida, Miami USA for their material and technical help in uploading videos and securing articles for literature review.

*Funding: No funding sources*

*Conflict of interest: None declared*

*Ethical approval: The study was approved by the institutional ethics committee*

## REFERENCES

- Catenacci M, Flyckt RL, Falcone T. Robotics in reproductive surgery: strengths and limitations. *Placenta.* 2011;32(3):232-7.
- Endometriosis Research Center. Understanding endometriosis: past, present and future, 2005. The National Women's health Information Council. Available at: <http://www.4woman.gov/HealthPro/healtharticle/march.htm>.
- Nezhat C, Lewis M, Kotikela S, Veeraswamy A, Saadat L, Hajhosseini B, et al. Robotic versus standard laparoscopy for the treatment of endometriosis. *Fertil Steril.* 2010;94:2758-60.
- Giudice LC, Kao LC. Endometriosis. *Lancet.* 2004;364:1789-99.
- Nezhat C, Hajhosseini B, King LP. Robotic-assisted laparoscopic treatment of bowel, bladder, and ureteral endometriosis. *JSLs.* 2011 Jul-Sep;15(3):387-92.
- Joel Cardenas-Goicoechea, Sarah Adams, Suneel B. Bhat, Thomas C. Randall. Surgical outcomes of robotic-assisted surgical staging for endometrial cancer are equivalent to traditional laparoscopic staging at a minimally invasive surgical center. *Gynecol Oncol.* 2010 May;117(2):224-8.
- Cheng YM, Wang ST, Chou CY. Serum CA-125 in preoperative patients at high risk for endometriosis. *Obstet Gynecol.* 2002;99:375-80.
- Liu C, Perisic D, Samadi D, Nezhat F. Robotic-assisted laparoscopic partial bladder resection for the treatment of infiltrating endometriosis. *J Minim Invasive Gynecol.* 2008 Nov-Dec;15(6):745-8.
- Ercoli A, D'asta M, Fagotti A, Fanfani F, Romano F, Baldazzi G, et al. Robotic treatment of colorectal endometriosis: technique, feasibility and short-term results. *Hum Reprod.* 2012;27(3):722-6.
- Ness RB, Cramer DW, Goodman MT, Kjaer SK, Mallin K, Mosgaard BJ, et al. Infertility, fertility drugs, and ovarian cancer: a pooled analysis of case-control studies. *Am J Epidemiol.* 2002;155:217-24.
- Brinton LA, Sakoda LC, Sherman ME, Frederiksen K, Kjaer SK, Graubard BI, et al. Relationship of benign gynecologic diseases to subsequent risk of ovarian and uterine tumors. *Cancer Epidemiol Biomarkers Prev.* 2005;14:2929-35.
- Magrina JF. Robotic surgery in gynecology. *Eur J Gynaecol Oncol.* 2007;28(2):77-82.
- Leddy, Laura Sigismund, Thomas S. Lendvay, Richard M. Satava. Robotic surgery: applications and cost effectiveness. *Open Access Surg.* 2010;3:99-107.
- Delaney CP, Lynch AC, Senagore AJ, Fazio VW. Comparison of robotically performed and traditional laparoscopic colorectal surgery. *Dis Colon Rectum.* 2003;46:1633-9.
- Lenihan JP Jr, Kovanda C, Seshadri-Kreaden U. What is the learning curve for robotic assisted gynecological surgery? *J Minim Invasive Gynecol.* 2008;15(5):589-94.
- Lasser MS, Patel CK, Elsamra SE, Renzulli JF, Haleblan GE, Pareek G. Dedicated robotics team reduces pre-surgical preparation time. *Indian J Urol.* 2012;28:263-6.
- Sutton CJG, Ewen SP, Whitelaw N, Haines P. Prospective, randomized, double blind controlled trial of laser laparoscopy in the treatment of pelvic pain associated with minimal, mild and moderate endometriosis. *Fertil Steril.* 1994;62:696-700.
- Parker JD, Sinaii N, Sears JH, Godoy H, Winkel C, Stratton P. Adhesion formation after laparoscopic excision of endometriosis and lysis of adhesions. *Fertil Steril.* 2005;84:1457-61.
- Nezhat C, Lavie O, Lemyre M, Unal E, Nezhat CH, Nezhat F. Robot-assisted laparoscopic surgery in gynecology: scientific dream or reality? *Fertil Steril.* 2009;91:2620-2.
- Nezhat C, Saberi NS, Shahmohamady B, Nezhat F. Robotic-assisted laparoscopy in gynecological surgery. *JSLs.* 2006;10(3):317-20.

DOI: 10.5455/2320-1770.ijrcog20150201

**Cite this article as:** Ramavath KK, Penalver MA, Mendez LE, Roza O. Hands behind the Robo-application of robotic surgery in the treatment of endometriosis: view point of an Indian Obgyn fellow in USA. *Int J Reprod Contracept Obstet Gynecol* 2015;4:202-9.